

Pseudodrusen and Incidence of Late Age-Related Macular Degeneration in Fellow Eyes in the Comparison of Age-Related Macular Degeneration Treatments Trials

Qiang Zhou, MD,¹ Ebenezer Daniel, MBBS, PhD,² Maureen G. Maguire, PhD,² Juan E. Grunwald, MD,² E. Revell Martin, BA,² Daniel F. Martin, MD,³ Gui-shuang Ying, PhD,² on behalf of the Comparison of Age-Related Macular Degeneration Treatments Trials Research Group*

Purpose: To evaluate the association between pseudodrusen and incidence of late age-related macular degeneration (AMD) in fellow eyes of patients with unilateral neovascular AMD (nAMD).

Design: Cohort study within the Comparison of AMD Treatments Trials (CATT).

Participants: Patients with neither nAMD nor geographic atrophy (GA) in the fellow eye at baseline.

Methods: Presence and type (dot, reticular, or confluent) of baseline pseudodrusen were assessed using digital color fundus photography (CFP) viewed under full color, green channel, and blue channel; red-free images; and fluorescein angiography (FA). Incidence of nAMD was based on monthly clinical examination and reading center evaluation of images at years 1 and 2. Incidence of GA was based on reading center evaluation of CFP and FA images at years 1 and 2. Associations of baseline pseudodrusen with incident nAMD and GA were summarized with adjusted risk ratios (aRRs) and their 95% confidence intervals (CIs) from multivariate Cox models, with adjustment of covariates identified through backward stepwise selection.

Main Outcome Measures: Incident nAMD and GA.

Results: Among 620 fellow eyes, 176 (28.4%) had baseline pseudodrusen (55% dot, 82% reticular, 35% confluent). Within 2 years, nAMD occurred in 54 eyes (30.7%) with pseudodrusen and in 72 eyes (16.2%) without pseudodrusen (aRR, 2.05; 95% CI, 1.43–2.93); GA occurred in 27 eyes (15.3%) with pseudodrusen and in 37 eyes (8.3%) without pseudodrusen (aRR, 1.89; 95% CI, 1.13–3.17); late AMD occurred in 73 eyes (41.5%) with pseudodrusen and in 101 eyes (22.8%) without pseudodrusen (aRR, 2.07; 95% CI, 1.51–2.83). Dot pseudodrusen were associated independently with nAMD (aRR, 2.53; 95% CI, 1.60–4.00), whereas confluent pseudodrusen were associated independently with GA (aRR, 4.35; 95% CI, 1.69–11.2). Eyes with pseudodrusen had increased incidence of late AMD regardless of whether the Age-Related Eye Diseases Study (AREDS) severity score was 2 (28.7% vs. 10.3%), 3 (34.9% vs. 13.7%), or 4 (50.5% vs. 32.0%).

Conclusions: In fellow eyes of CATT participants, pseudodrusen were associated independently with a higher incidence of both nAMD and GA. Dot pseudodrusen were associated with nAMD, whereas confluent pseudodrusen were associated with GA. Pseudodrusen should be considered along with the AREDS severity score for predicting late AMD. *Ophthalmology* 2016;123:1530-1540 © 2016 by the American Academy of Ophthalmology.



Supplemental material is available at www.aaojournal.org.

Pseudodrusen were reported first by Mimoun et al¹ in 1990 as a special type of drusen in the macula of patients with age-related macular degeneration (AMD). Later, the terms *reticular drusen*, *reticular pseudodrusen*, *reticular macular disease* or *reticular macular lesions*, and *subretinal drusenoid deposits* were used to describe this type of drusen.^{2–8} Population-based studies, such as the Beaver Dam Eye Study and the Blue Mountains Eye Study, found that eyes with early AMD features and pseudodrusen demonstrated on color fundus photography (CFP) were 4 to 6 times more likely to progress to late AMD within 5 years when matched to eyes without pseudodrusen but with otherwise similar

early AMD features.^{9–11} Several clinical studies also have demonstrated a strong association between pseudodrusen and the development of late AMD.^{3,7,8,12–14} However, the specific association of pseudodrusen with neovascular AMD (nAMD) or with geographic atrophy (GA) is not clear because these studies were limited by a small number of incident cases.

It is well known that when nAMD is present in one eye, the fellow eye is at high risk of demonstrating late AMD.^{15–17} A meta-analysis provided incidence estimates for nAMD in the fellow eye of 12.2% by 1 year after nAMD detection in the first eye and of 26.8% by 4 years.¹⁸ These

estimates are much higher than the estimates of the annual incidence of 0.57% to 1.13% in white Americans 75 to 84 years of age.¹⁹ This elevated risk is independent of treatment with ranibizumab or bevacizumab for nAMD.²⁰ A few clinical studies with sample sizes ranging from 20 to 271 patients have evaluated the association of pseudodrusen with development of nAMD and GA in the fellow eye of patients with unilateral nAMD.^{21–25} However, the conclusions from these studies were inconsistent, most likely because of small numbers of incident cases of nAMD and GA and differences in the imaging methods used to detect pseudodrusen.

The Comparison of Age-Related Macular Degeneration Treatments Trials (CATT) provided a large cohort of patients with nAMD in the study eye treated with randomly assigned ranibizumab or bevacizumab through 2 years.^{26,27} This well-characterized cohort provided a unique opportunity to evaluate the association of pseudodrusen with incidence of nAMD and GA in the fellow eye of patients with unilateral nAMD.

Methods

Details on the CATT study design and methods have been reported in our previous publications^{20,26,27} and at ClinicalTrials.gov (identifier, NCT00593450). Only features relevant to the evaluation of pseudodrusen at baseline and assessment of nAMD and GA in the fellow eye are noted here.

Study Participants

Participants were enrolled from 43 clinical centers in the United States between February 2008 and December 2009. The study enrollment criteria included age of 50 years or older, untreated active neovascularization resulting from AMD in the study eye (1 eye per participant), and visual acuity between 20/25 and 20/320 on electronic visual acuity testing. Active neovascularization was defined by the presence of leakage on fluorescein angiography (FA) and fluid on time-domain optical coherence tomography (OCT). The study was approved by an institutional review board associated with each center. All patients provided written informed consent.

At enrollment, participants provided information on demographic characteristics and medical history, including a history of cardiovascular diseases and hypertension. Participants were randomized to 1 of the 4 treatment groups: (1) ranibizumab monthly, (2) bevacizumab monthly, (3) ranibizumab as needed (pro re nata [PRN]), and (4) bevacizumab PRN. At 1 year, participants initially assigned to monthly treatment retained their drug assignment, but were reassigned randomly to either monthly or PRN treatment. Participants initially assigned to PRN treatment retained both their drug and regimen for year 2.

Study Procedures

At enrollment, patients were examined by study-certified retina specialists. The retina specialist indicated whether there was a history of nAMD or active nAMD in the fellow eye. Patients underwent bilateral stereoscopic CFP, red-free (RF) imaging, and FA that included stereo images of the macula of the fellow eye at 2 and 10 minutes after dye injection. Follow-up examinations for both the study eye and the fellow eye were scheduled every 28 days for 2 years. During each examination, the study retina specialist completed case report forms with specific questions regarding whether there had been any treatment for nAMD in the fellow eye since the last CATT examination or whether treatment

was scheduled on the day of the examination. At years 1 and 2, CFP and FA also were performed in both study eyes and fellow eyes. Certified graders at the CATT Fundus Photograph Reading Center reviewed images acquired at baseline and years 1 and 2 for nAMD morphologic features in the study eye and the presence of nAMD, GA, and scar in the fellow eye.²⁸ The presence of large drusen (>125 μ m) and pigment abnormalities (hyperpigmentation or depigmentation) at baseline in the fellow eye also were graded.

Patients were included in this study if the fellow eye did not have any evidence of neovascularization, scar, or GA at baseline on either clinical examination or image evaluation by the reading center using CFP and FA. Incident nAMD in the fellow eye was considered present at the earliest follow-up visit when the examining retina specialist indicated that treatment for nAMD in the fellow eye had occurred since the last study examination or would occur on the day of the study visit. In addition, eyes confirmed to have leakage on FA or a new scar on CFP at years 1 or 2 by the Director of the Fundus Photograph Reading Center (E.D.) were classified as having nAMD. Incident GA was identified from reading center evaluation of images from year 1 or 2. The diagnosis of GA required the presence within the macular vascular arcades of 1 or more patch of 250 μ m or more in longest linear dimension of partial or complete depigmentation on the CFP that had 1 or more of these additional characteristics: sharply demarcated borders seen on CFP, FA, or both; visibility of underlying choroidal vessels; excavated or punched out appearance on stereoscopy of CFP or FA; or uniform hyperfluorescence bounded by sharp borders on late-phase angiography.²⁹

Pseudodrusen Evaluation

Baseline digital CFP images from fellow eyes of CATT participants were evaluated for the presence and type of pseudodrusen by one of the authors (Q.Z.), who was masked to the status of late AMD during follow-up. To enhance the visibility of pseudodrusen, CFP images were reviewed with full color, only the green channel, or only the blue channel in Photoshop (Photoshop CS6, version 13.0; Adobe System, Inc., San Jose, CA). Pseudodrusen usually are more visible when viewing CFP images with the green or blue channel than in full color.^{2,8} In Photoshop, the command “Channels” was used to display channels for each color (red, green, and blue) plus a composite channel (i.e., original image) of the RGB (full-color) image. If needed, adjustment of brightness and contrast was made to improve the view of pseudodrusen. Besides the CFP, digital RF fundus photographs also were used to aid in the detection of pseudodrusen that were not clearly apparent when viewing CFPs. In addition, FA images were used to distinguish pseudodrusen from other drusen (soft, hard, or cuticular drusen). We graded the presence of pseudodrusen (none, questionable, yes) and the type of pseudodrusen (dot, reticular, and confluent; [Figs 1, 2, and 3](#)). When the presence of pseudodrusen was questionable, the consensus results after review with the Director of the Fundus Photograph Reading Center (E.D.) and a senior certified grader (R.M.) were used for data analysis.

Our definition of pseudodrusen on CFP was based primarily on 2 previous studies.^{30,31} In full-color and green- or blue-channel viewing of CFP images, pseudodrusen were considered to be present if 5 or more drusen were brighter in the green or blue channel than in full color ([Figs 1A, 2A, and 3A](#)).^{2,13,32} The method to determine the presence of pseudodrusen on RF images was similar to that on green- or blue-channel images ([Figs 1B, 2B, and 3B](#)). On FA, pseudodrusen are different from regular drusen in that pseudodrusen are not visible in the early phase and generally are not visible in the middle and late phases ([Figs 1E, F; 2E, F; and 3E, F](#))^{1,7,8,12,33–35} or show only faint fluorescence in the late phase.^{3,36} In contrast, regular drusen usually are hyperfluorescent in the early phase and stain in the late phase ([Fig 1E, F](#)).

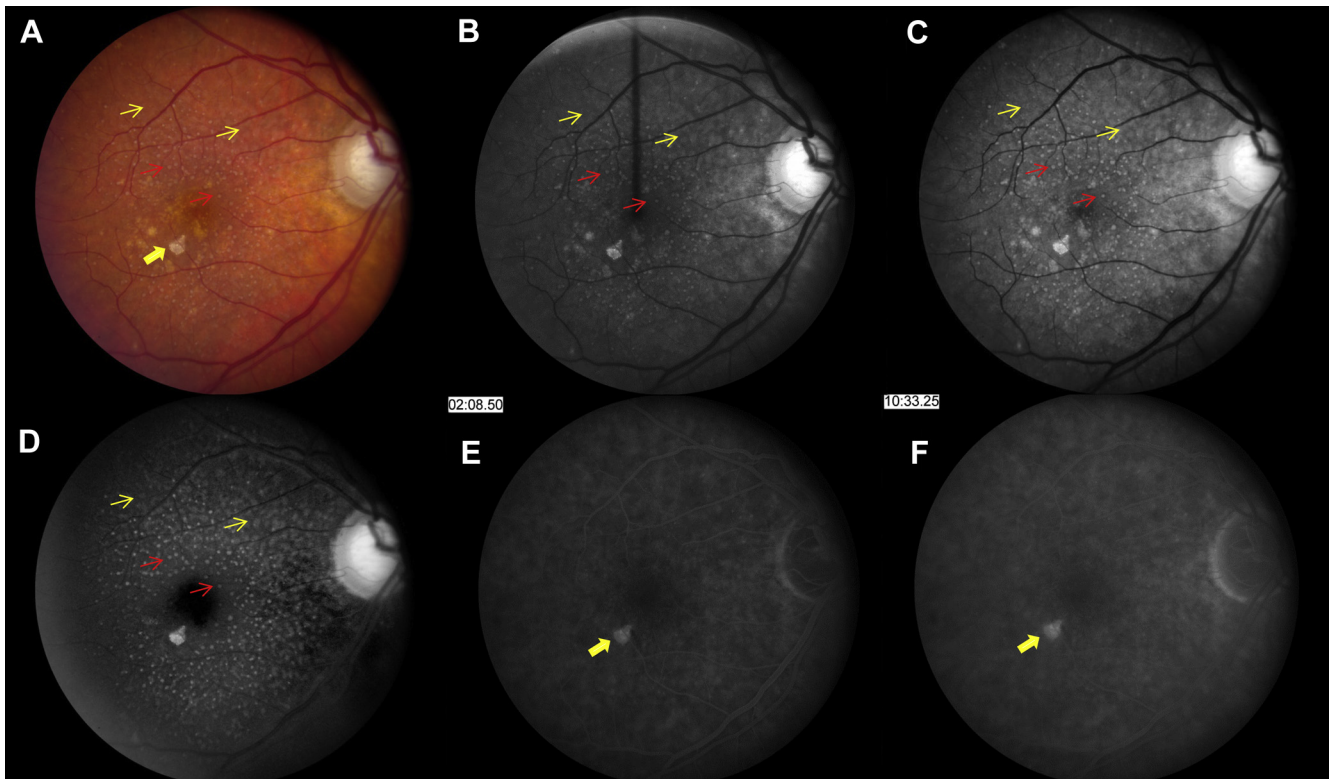


Figure 1. Dot and reticular pseudodrusen in a fellow eye shown on (A) original color fundus photography (CFP), (B) red-free imaging, (C) green-channel imaging, (D) blue-channel imaging, (E) early phase fluorescein angiography (FA), (F) and late phase FA. Dot pseudodrusen (red thin arrow) are more visible than reticular pseudodrusen (yellow thin arrow) in CFP. Both of them are more obvious in the blue-channel image. Pseudodrusen are not visible on FA; drusen (yellow thick arrow) are hyperfluorescent on FA.

Based on the pseudodrusen features on CFP, pseudodrusen were classified further as dot, reticular, and confluent.^{30,31} Dot pseudodrusen appear as discrete, round to oval dots with areas between dot pseudodrusen exhibiting no marked changes (Fig 1A). Reticular pseudodrusen form a complex network of curvilinear lesions or interlocking ribbons, with areas between reticular pseudodrusen exhibiting no marked changes (Fig 2A). Confluent pseudodrusen are lesions that appear merged or running together (Fig 3A). Dot and reticular pseudodrusen can be present separately or together, whereas confluent pseudodrusen are almost always present with dot or reticular pseudodrusen.

Quality Assurance

We randomly selected 60 fellow eyes to evaluate intergrader and intragrader agreement for grading presence and type of pseudodrusen. All images of the selected fellow eyes were graded and regraded by the grader (Q.Z.) at an interval of approximately 2 months. In addition, the selected images also were graded by a certified senior grader (R.M.) in the CATT Fundus Photograph Reading Center of the University of Pennsylvania. The results for intragrader and intergrader agreement are reported in Table 1 (available at www.aaojournal.org). The presence of any pseudodrusen had good intragrader agreement (95% agreement; weighted κ , 0.89) and intergrader agreement (83% agreement; weighted κ , 0.59). Presence of each type of pseudodrusen had similar intragrader agreement (90%–92% agreement; weighted κ , 0.79–0.84) and intergrader agreement (77%–80% agreement; weighted κ , 0.54–0.61).

Statistical Analyses

The characteristics of participants with or without baseline pseudodrusen in the fellow eye were compared using the *t* test for means and the Fisher exact test for proportions. The Age-Related Eye Disease Study (AREDS) severity score was calculated by adding for each eye 1 point for any large druse, 1 point for any pigment abnormality (hyperpigmentation or depigmentation), and 2 points for late AMD.¹⁷ Because the study eye already had nAMD at baseline, the AREDS score of CATT participants at baseline was either 2, 3, or 4. The associations between presence of pseudodrusen or type of pseudodrusen at baseline and the incidence of nAMD, GA, or late AMD (nAMD, GA, or both) in the fellow eye in 2 years were assessed using risk ratios (RRs), and their 95% confidence intervals (CIs) from univariate and multivariate Cox regression models. In the multivariate Cox regression models, we started with the model that included age, gender, drug, dosing regimen, smoking status, diabetes, hypertension, dietary supplement use, and the AREDS severity score. Backward stepwise selection of covariates was applied, and the final multivariate Cox model included only the statistically significant covariates. The Kaplan-Meier method was used to estimate the cumulative incidence of nAMD, GA, and late AMD in fellow eyes by baseline pseudodrusen status and was stratified by baseline AREDS severity score. For the analyses involving types of pseudodrusen, indicator variables for each type of pseudodrusen, that is, dot pseudodrusen (yes or no), reticular pseudodrusen (yes or no), and confluent pseudodrusen (yes or no), were included in the same multivariate model to evaluate the independent association of each type of pseudodrusen with nAMD,

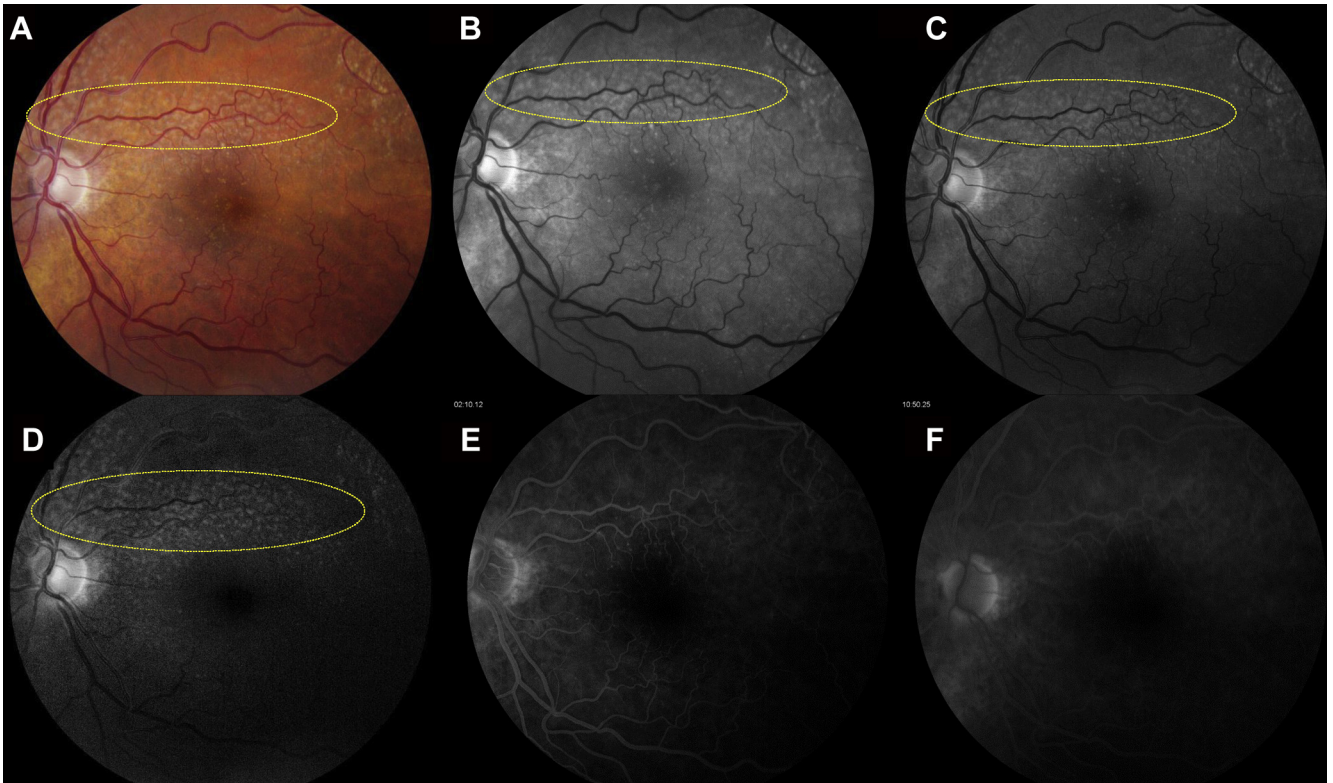


Figure 2. Reticular pseudodrusen (mainly inside the yellow ellipse) on (A) color fundus photography, (B) red-free imaging, (C) green-channel imaging, (D) blue-channel imaging, (E) early phase fluorescein angiography (FA), and (F) late phase FA. Pseudodrusen are not visible on FA. Parts (A), (C), and (D) were enhanced for brightness, and parts (C) and (D) were enhanced for contrast.

GA, and late AMD. All statistical analyses were performed using SAS software version 9.4 (SAS Institute, Inc., Cary, NC).

Results

Among 1185 CATT subjects, 458 fellow eyes had nAMD, 74 had GA at baseline, and 33 eyes had insufficient image quality for pseudodrusen evaluation, leaving 620 CATT participants (52.3%) eligible for this analysis (Fig 4, available at www.aaojournal.org). Among the 620 patients, 176 (28.4%) had pseudodrusen in the fellow eye at baseline. Table 2 shows the comparison of patient characteristics for fellow eyes with baseline pseudodrusen with those without pseudodrusen. Patients with pseudodrusen were older (mean age, 81.3 years vs. 76.9 years; $P < 0.0001$) and were more likely to be women (79.0% vs. 53.4%; $P < 0.0001$), less likely to be a former or current smoker (48.9% vs. 64.4%; $P = 0.002$), and less likely to be diabetic (13.6% vs. 20.7%; $P = 0.04$). There were no differences in reported history of cardiovascular diseases ($P = 0.56$), hypertension ($P = 0.70$), or dietary supplements ($P = 0.23$). The proportions in the group with pseudodrusen and the group without pseudodrusen were similar for large drusen (68.2% vs. 72.3%; $P = 0.31$) and for an AREDS severity score of 4 (61.9% vs. 61.0%; $P = 0.16$), but the proportion with hyperpigmentation was higher in eyes with pseudodrusen than eyes without pseudodrusen (84.7% vs. 74.8%; $P = 0.008$).

Among the 176 eyes with pseudodrusen, 96 (54.5%) had dot pseudodrusen, 145 (82.4%) had reticular pseudodrusen, and 61 (34.7%) had confluent pseudodrusen. Two or more types of pseudodrusen were present 104 eyes (59%). Among the 96 eyes

with dot pseudodrusen, 44 (45.8%) also had reticular pseudodrusen, 2 (2.0%) also had confluent pseudodrusen, and 22 (22.9%) had all 3 types. Among the 69 eyes with confluent pseudodrusen, 36 (59.0%) also had reticular pseudodrusen, 2 (2.9%) also had dot pseudodrusen, and 22 (31.9%) had all 3 types.

During the 2-year follow-up, nAMD developed in 126 fellow eyes (20.3%) and GA developed in 64 fellow eyes (10.3%); thus, late AMD (nAMD, GA, or both) developed in a total of 174 eyes (28.1%). Among 16 eyes in which both nAMD and GA developed, GA was observed in 12 eyes (75%) at the same visit or a later visit when nAMD was first observed or treated.

During the 2-year follow-up, nAMD developed in 54 fellow eyes (30.7%) with pseudodrusen and 72 fellow eyes (16.2%) without pseudodrusen. The cumulative incidence of nAMD during 2-year follow-up is shown in Figure 5. On univariate analysis, the presence of baseline pseudodrusen was associated significantly with a higher risk of nAMD developing (RR, 2.11; 95% CI, 1.48–3.00; $P < 0.0001$; Table 3). This association persisted (adjusted RR [aRR], 2.20; 95% CI, 1.51–3.19; $P < 0.0001$) after adjustment for the significant covariates (i.e., AREDS severity score [$P = 0.02$] and use of dietary supplements [$P = 0.03$]). In the multivariate analyses adjusted by AREDS severity score and use of dietary supplements, both dot pseudodrusen (aRR, 2.74; $P < 0.0001$) and reticular pseudodrusen (aRR, 1.71; $P = 0.005$) were associated with nAMD (Table 3, middle columns). However, when all 3 types of pseudodrusen were considered simultaneously in a multivariate model adjusted by AREDS severity score and use of dietary supplements, only dot pseudodrusen were associated independently with nAMD (aRR, 2.53; 95% CI, 1.60–4.00; $P < 0.0001$; Table 3, right columns).

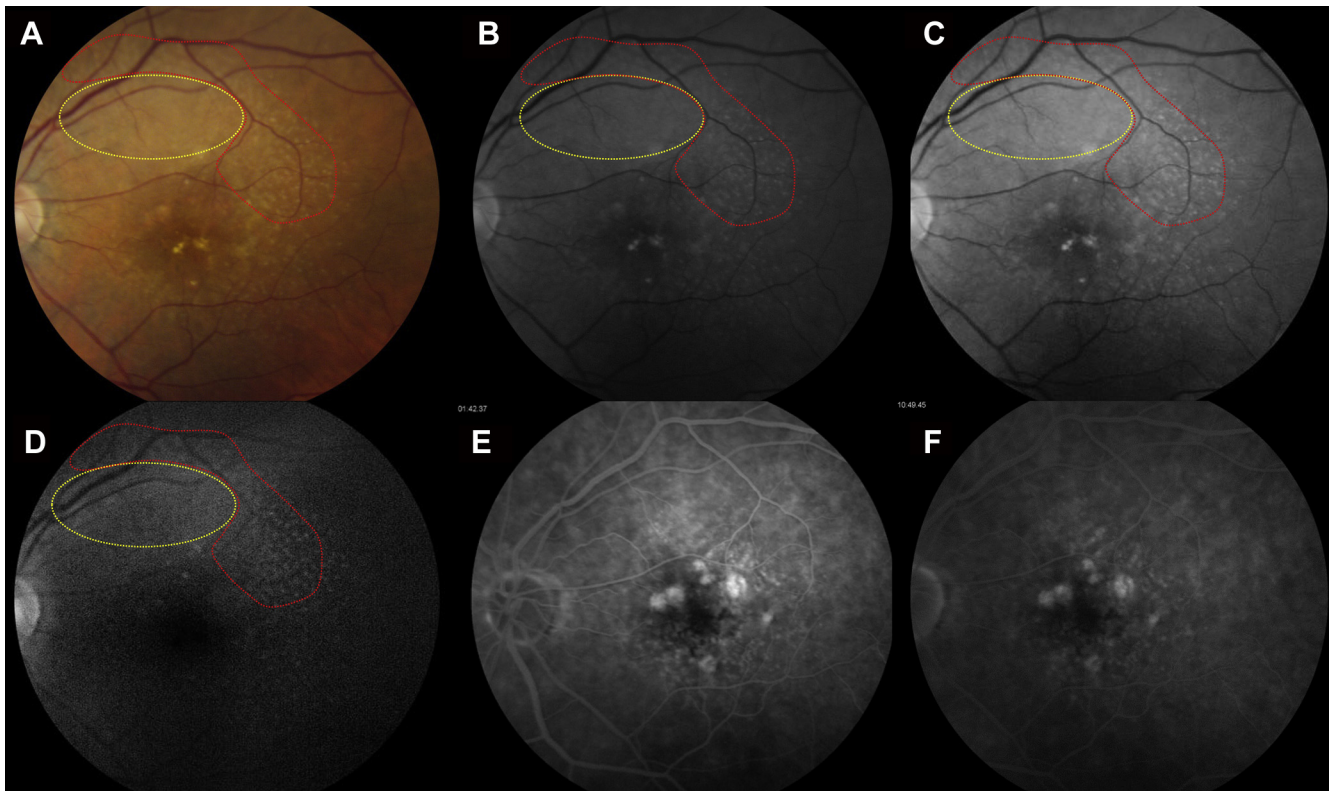


Figure 3. Confluent pseudodrusen (inside the yellow ellipse) surround by reticular pseudodrusen (mainly inside the red ellipse) on (A) color fundus photography, (B) red-free imaging, (C) green-channel imaging, (D) blue-channel imaging, (E) early phase fluorescein angiography (FA), and (F) late phase FA. Pseudodrusen are not visible on FA and show only background fluorescence in the early phase and faint fluorescent stain in the late phase. Parts (A), (C), and (D) were enhanced for brightness, and parts (C) and (D) were enhanced for contrast.

Table 2. Baseline Characteristics of Patients by Presence of Pseudodrusen in the Fellow Eye

Baseline Characteristics	All Subjects (n = 620)	Pseudodrusen Absent (n = 444)	Pseudodrusen Present (n = 176)	P Value
Mean age (SD), yrs	78.1 (7.6)	76.9 (7.5)	81.3 (6.8)	<0.0001
Female, no. (%)	376 (60.7)	237 (53.4)	139 (79.0)	<0.0001
Smoking status, no. (%)				0.002
Never	248 (40.0)	158 (35.6)	90 (51.1)	
Former	316 (51.0)	243 (54.7)	73 (41.5)	
Current	56 (9.0)	43 (9.7)	13 (7.4)	
Presence of diabetes, no. (%)	116 (18.7)	92 (20.7)	24 (13.6)	0.04
Presence of hypertension, no. (%)	432 (69.7)	307 (69.1)	125 (71.0)	0.70
History of cardiovascular diseases, no. (%)	129 (20.8)	95 (21.4)	34 (19.3)	0.56
Use of dietary supplements, no. (%)				0.23
No	63 (10.2)	51 (11.5)	12 (6.8)	
Antioxidants and zinc	396 (63.9)	280 (63.1)	116 (65.9)	
Other supplements	161 (26.0)	113 (25.5)	48 (27.3)	
Fellow eye characteristics, no. (%)				
Any large drusen	441 (71.1)	321 (72.3)	120 (68.2)	0.31
Hyperpigmentation	481 (77.6)	332 (74.8)	149 (84.7)	0.008
Depigmentation	110 (17.7)	72 (16.2)	38 (21.6)	0.11
AREDS severity score, no. (%)				0.16
2	64 (10.3)	52 (11.7)	12 (6.8)	
3	176 (28.4)	121 (27.3)	55 (31.3)	
4	380 (61.3)	271 (61.0)	109 (61.9)	

AREDS = Age-Related Eye Diseases Study; SD = standard deviation.

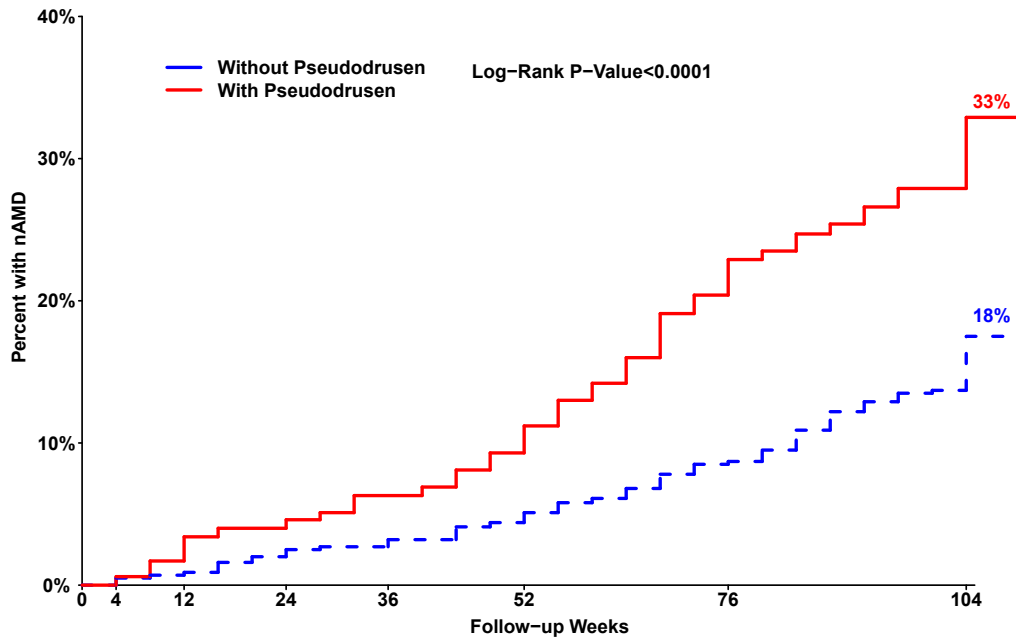


Figure 5. Kaplan-Meier curve showing the development of neovascular age-related macular degeneration (nAMD) in eyes by presence of baseline pseudodrusen.

During the 2-year follow-up, GA developed in 27 fellow eyes (15.3%) with pseudodrusen and in 37 fellow eyes (8.3%) without pseudodrusen (RR, 1.89; 95% CI, 1.15–3.11; $P = 0.01$; Table 3). After adjustment for the significant covariate (i.e., AREDS severity score [$P = 0.004$]), the association persisted (aRR, 1.89; 95% CI, 1.13–3.17; $P = 0.02$). In the multivariate analyses adjusted by AREDS severity score, both reticular pseudodrusen (aRR, 1.81; $P = 0.03$) and confluent pseudodrusen (aRR, 3.60; $P < 0.0001$) were associated with GA (Table 3, middle columns). However, when all 3 types of pseudodrusen were considered simultaneously in a multivariate model, only confluent pseudodrusen were associated independently with GA (aRR, 4.35; 95% CI, 1.69–11.2; $P = 0.002$; Table 3, right columns).

When eyes with nAMD and GA were considered together for the development of late AMD, fellow eyes with pseudodrusen had a higher risk of late AMD developing (aRR, 2.07; 95% CI, 1.51–2.83; $P < 0.0001$; Table 3) after adjustment for AREDS severity score ($P < 0.0001$) and use of dietary supplements ($P = 0.03$). In the multivariate analysis adjusted by AREDS severity score and use of dietary supplements, dot pseudodrusen (aRR, 2.12; $P < 0.0001$), reticular pseudodrusen (aRR, 1.74; $P = 0.0009$), and confluent pseudodrusen (aRR, 2.15; $P < 0.0001$) all were associated significantly with late AMD (Table 3, middle columns). When all 3 types of pseudodrusen were considered simultaneously in a multivariate model, dot pseudodrusen (aRR, 1.76; $P = 0.009$) were associated significantly with late AMD, and confluent pseudodrusen (aRR, 1.64; $P = 0.07$; Table 3) were associated marginally with late AMD.

Most CATT participants (89.7%) had a baseline AREDS score of 3 or 4. An increased incidence of nAMD, GA, and late AMD associated with pseudodrusen was seen across each level of AREDS severity score (Table 4, available at www.aaojournal.org). In patients with an AREDS severity score of 3, the cumulative incidence of late AMD was 34.9% for fellow eyes with pseudodrusen and 13.7% for eyes without pseudodrusen. For patients with an AREDS severity score of 4, the cumulative incidence of late AMD was 50.5% for fellow eyes with

pseudodrusen and 32.0% for eyes without pseudodrusen at baseline. The Kaplan-Meier curves showed higher risk of nAMD (Fig 6), GA (Fig 7, available at www.aaojournal.org), and late AMD (Fig 8, available at www.aaojournal.org) developing over 2 years in fellow eyes with pseudodrusen than in those without pseudodrusen with an AREDS score of 3 or 4. Baseline pseudodrusen improves the prediction of late AMD; the area under receiver operating characteristic curve increased from 0.64 (predicted by AREDS severity score and dietary supplement use) to 0.68 ($P = 0.004$) when baseline pseudodrusen was added into the prediction model.

Discussion

In this study, we evaluated the prevalence of pseudodrusen as ascertained from CFP and FA and the association of pseudodrusen with incidence of nAMD and of GA in the fellow eye of CATT participants with unilateral baseline nAMD. We found that more than one fourth of fellow eyes had pseudodrusen at baseline, and fellow eyes with baseline pseudodrusen had an approximately 2 times higher incidence of nAMD and GA than those without pseudodrusen. The analyses suggest that dot pseudodrusen had the strongest association with nAMD, whereas confluent pseudodrusen had the strongest association with GA. The risk conferred by pseudodrusen was incremental to the risk of late AMD developing associated with each AREDS severity level, implying that pseudodrusen should be considered as another independent predictor along with large drusen and pigment abnormalities.

Pseudodrusen in this study were detected using the digital CFP images viewed under full color, blue channel only, and green channel only, supplemented by the RF image and FA. Use of at least 2 imaging methods has been

Table 3. Association of Baseline Pseudodrusen in the Fellow Eye with Incidence of Neovascular Age-Related Macular Degeneration, Geographic Atrophy, and Late Age-Related Macular Degeneration in the Fellow Eye

Pseudodrusen at Baseline	No.	Incidence, No. (%)	Unadjusted Analysis		Adjusted Analysis*		Adjusted Analysis [†]	
			Risk Ratio (95% Confidence Interval)	P Value	Risk Ratio (95% Confidence Interval)	P Value	Risk Ratio (95% Confidence Interval)	P Value
nAMD								
Any								
No	444	72 (16.2)	1.00		1.00			
Yes	176	54 (30.7)	2.11 (1.48–3.00)	<0.0001	2.05 (1.43–2.93)	<0.0001		
Dot								
No	524	90 (17.2)	1.00		1.00		1.00	
Yes	96	36 (37.5)	2.55 (1.73–3.75)	<0.0001	2.74 (1.85–4.07)	<0.0001	2.53 (1.60–4.00)	<0.0001
Reticular								
No	475	84 (17.7)	1.00		1.00		1.00	
Yes	145	42 (29.0)	1.81 (1.25–2.61)	0.002	1.71 (1.18–2.50)	0.005	1.24 (0.76–2.02)	0.40
Confluent								
No	559	109 (19.5)	1.00		1.00		1.00	
Yes	61	17 (27.9)	1.46 (0.88–2.44)	0.15	1.38 (0.82–2.31)	0.23	0.87 (0.47–1.60)	0.66
GA								
Any								
No	444	37 (8.3)	1.00		1.00			
Yes	176	27 (15.3)	1.89 (1.15–3.11)	0.01	1.89 (1.13–3.17)	0.02		
Dot								
No	524	56 (10.7)	1.00		1.00		1.00	
Yes	96	8 (8.3)	0.77 (0.37–1.62)	0.50	0.82 (0.38–1.76)	0.61	0.53 (0.23–1.23)	0.14
Reticular								
No	475	41 (8.6)	1.00		1.00		1.00	
Yes	145	23 (15.9)	1.89 (1.13–3.15)	0.01	1.81 (1.06–3.08)	0.03	0.98 (0.41–2.35)	0.96
Confluent								
No	559	47 (8.4)	1.00		1.00		1.00	
Yes	61	17 (27.9)	3.45 (1.98–6.01)	<0.0001	3.60 (1.97–6.58)	<0.0001	4.35 (1.69–11.2)	0.002
Late AMD								
Any								
No	444	101 (22.8)	1.00		1.00		1.00	
Yes	176	73 (41.5)	2.09 (1.55–2.83)	<0.0001	2.07 (1.51–2.83)	<0.0001		
Dot								
No	524	134 (25.6)	1.00		1.00		1.00	
Yes	96	40 (41.7)	1.91 (1.34–2.71)	0.0004	2.12 (1.47–3.08)	<0.0001	1.76 (1.15–2.70)	0.009
Reticular								
No	475	116 (24.4)	1.00		1.00		1.00	
Yes	145	58 (40.0)	1.84 (1.34–2.52)	0.0002	1.74 (1.25–2.42)	0.0009	1.11 (0.70–1.76)	0.66
Confluent								
No	559	143 (25.6)	1.00		1.00		1.00	
Yes	61	31 (50.8)	2.20 (1.49–3.24)	<0.0001	2.15 (1.43–3.23)	<0.0001	1.64 (0.97–2.78)	0.07

AMD = age-related macular degeneration; AREDS = Age-Related Eye Diseases Study; GA = geographic atrophy; nAMD = neovascular age-related macular degeneration.

*Adjusted by AREDS severity score and dietary supplement use for nAMD and late AMD; adjusted by AREDS severity score for GA.

[†]Besides the adjustment of AREDS severity score and dietary supplement use for nAMD and late AMD and adjustment by AREDS severity score for GA, the multivariate model also was adjusted by the existence of each type of pseudodrusen by including indicator variables for dot pseudodrusen (yes or no), reticular pseudodrusen (yes or no), and confluent pseudodrusen (yes or no) to evaluate the independent association of each type of pseudodrusen with late AMD.

recommended for accurate detection, with spectral-domain (SD) OCT and confocal scanning laser ophthalmoscopy being the most sensitive and specific image methods for pseudodrusen detection.^{37,38} At enrollment for CATT (between February 2008 and December 2009), time-domain OCT images were obtained because SD OCT was not yet available to most of the participating clinical centers. Although standard full-color viewing of CFP has been reported to have the lowest sensitivity for detection of pseudodrusen (36%),^{23,38} viewing digital CFP images with the green or blue channels and RF photographs improves

pseudodrusen detection. Smith et al⁸ reported that CFP images viewed in the green and blue channels had a sensitivity of 88% to detect pseudodrusen when compared with indocyanine green angiography. Similarly, Ueda-Arakawa et al³⁷ reported 76% sensitivity and 100% specificity when pseudodrusen were viewed on images with the blue channel. Pseudodrusen were detected with 100% specificity on RF images, although with lower sensitivity (48%) than on other imaging methods (blue light autofluorescence, infrared photography, and SD OCT).²³ Spaide and Curcio³² speculated that the reason

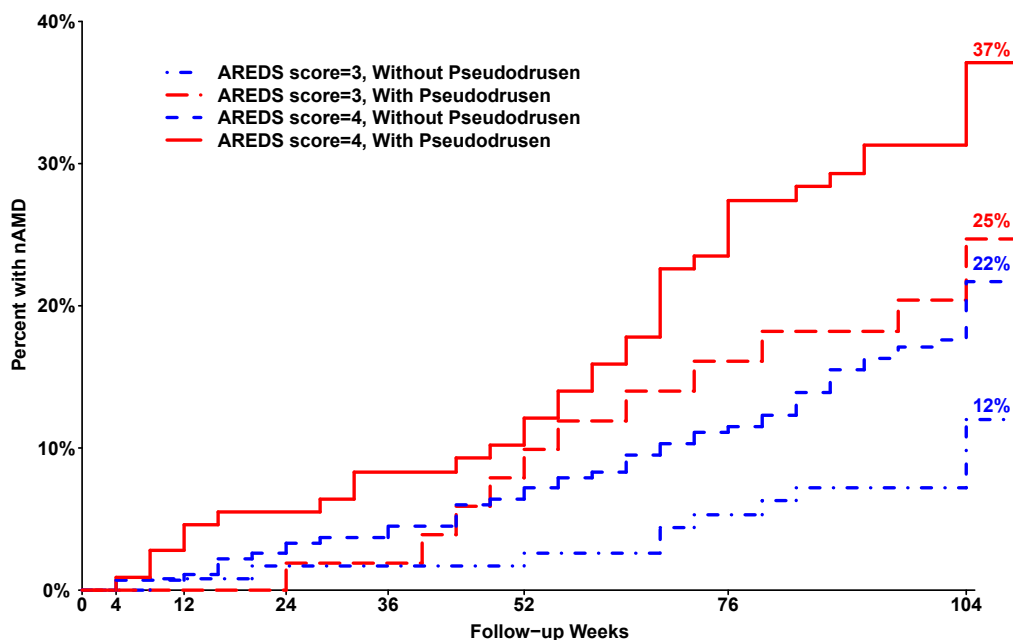


Figure 6. Kaplan-Meier curve for the development of neovascular age-related macular degeneration (nAMD) by presence of baseline pseudodrusen and Age-Related Eye Diseases Study (AREDS) severity score.

pseudodrusen are more visible in blue light is that pseudodrusen are on the top of the retinal pigment epithelium (RPE) and therefore do not have any blue light attenuation from the RPE. In contrast, regular drusen are below the RPE. Our study also used FA to distinguish pseudodrusen from other drusen (soft, hard, or cuticular drusen) based on the property that pseudodrusen are not visible in the early phase and generally are not visible in the middle and late phases, although they sometimes show faint fluorescence in the late phase. The absence of pseudodrusen on FA (especially in the early phase) has been reported in several previous studies.^{1,7,8,12,33–35} Rudolf et al³⁴ proposed that the RPE acts as an intact outer blood–retinal barrier to prevent absorption of fluorescein; thus, pseudodrusen lying over the RPE are not visible on FA, whereas drusen under the RPE are stained by fluorescein. All of these findings suggest that the imaging methods (CFP images in full-color view or viewed in green or blue channels, RF imaging, and FA) used in this study correctly identified most pseudodrusen and did not incorrectly identify other retinal abnormalities as pseudodrusen.

In recent years, a few cohort studies have evaluated the association of pseudodrusen with the incidence of late AMD in the fellow eye of patients with unilateral nAMD.^{21–25} In the first study by Pumariega et al,²¹ pseudodrusen were associated with increased risk of both nAMD (RR, 1.7; 95% CI, 1.2–2.4) and GA (RR, 2.0; 95% CI, 1.1–3.6). In a more recent study by Finger et al,²² pseudodrusen in the fellow eye at baseline were associated with only increased risk of GA (RR, 4.9; 95% CI, 1.1–22.9), and were not associated with nAMD (RR, 1.2; 95% CI, 0.7–1.9). However, Hogg et al²³ found that pseudodrusen were associated significantly with nAMD (RR, 5.5; 95% CI,

1.1–28.8), but no strong conclusions could be reached regarding the association with GA because only 5 cases were detected. Two other studies from Asia concluded that pseudodrusen were associated significantly with nAMD.^{24,25} In our study, which had the largest sample size, we found that pseudodrusen in the fellow eye are associated significantly with an approximately 2 times higher risk of both nAMD and GA than those eyes without pseudodrusen. These results were consistent with previous studies for nAMD,^{21,23–25} GA,^{21,22} and late AMD,^{21,23} respectively.

In contrast to previous cohort studies of pseudodrusen in the fellow eye, our study classified pseudodrusen into 3 types (dot, reticular, and confluent). Among 176 eyes with pseudodrusen, approximately 55% had dot pseudodrusen, 82% had reticular pseudodrusen, and 35% had confluent pseudodrusen. In 2012, Lee et al³¹ first classified pseudodrusen into 3 types (discrete, branching, and confluent) based on their appearance on CFP. Suzuki et al³⁰ later proposed another classification based on CFP and infrared scanning laser ophthalmoscopy that classified pseudodrusen into dot, ribbon, and peripheral pseudodrusen. In the classification by Suzuki et al, the dot pattern was similar to the discrete pattern and the ribbon pattern was similar to branching or reticular pseudodrusen. Suzuki et al also mentioned another uncommon type, peripheral pseudodrusen, which are located primarily peripheral to the perifoveal region, outside the Early Treatment Diabetic Retinopathy Study grid.³⁰ In our study, we found only 3 fellow eyes with peripheral pseudodrusen located outside the Early Treatment Diabetic Retinopathy Study grid (Fig 9, available at www.aajournal.org). Suzuki et al³⁰ also observed that dot pseudodrusen had a bulls-eye target configuration on infrared scanning laser ophthalmoscopy. We found a

similar appearance on CFP for dot pseudodrusen, which typically were surrounded by a dark halo (Fig 10, available at www.aaojournal.org). This feature is more visible when viewing images in the green or blue channels and RF images than when viewing them with full color on CFP. We used this feature as one of the characteristics to distinguish dot pseudodrusen from regular drusen.

Our study is unique in that it evaluated the association of each type of pseudodrusen (dot, reticular, and confluent) with late AMD. We found that dot pseudodrusen were associated independently with an approximately 3-fold increased risk for development of nAMD, whereas confluent pseudodrusen were associated independently with a 4-fold increased risk for development of GA when all 3 types of pseudodrusen were considered simultaneously along with the AREDS severity score in a multivariate model. Although reticular pseudodrusen were associated significantly with nAMD in a multivariate model without adjustment for the other 2 types of pseudodrusen, the association became weaker after adjustment for dot and confluent pseudodrusen. Similarly, reticular pseudodrusen were associated significantly with GA in a multivariate model without adjustment for the other 2 types of pseudodrusen; however, the association became weaker after adjustment for dot and confluent pseudodrusen. The fact that the association between reticular pseudodrusen and late AMD became weaker when adjusted for the presence of the other 2 types of pseudodrusen suggests that these other 2 types may be the strongest risk factors. Our findings on the independent association of confluent pseudodrusen with GA are consistent with the findings of Lee et al, who found that eyes with confluent pseudodrusen had a significantly higher prevalence of GA and speculated that the pseudodrusen were a progressive disease from initial localized dot pseudodrusen to final confluent pseudodrusen.³¹ Our results also validated the speculation of Suzuki et al³⁰ that different pseudodrusen types may result in different risks of progression to late AMD. Based on the different appearance in various imaging methods, it may be that different types of pseudodrusen result from different pathogenic mechanisms and may signal different processes in the development of nAMD and GA.³⁰

Although the exact mechanism for the association of pseudodrusen with nAMD and GA is not known, pseudodrusen are related to lower choroidal thickness,^{39–44} which may result in decreased choroidal perfusion and subsequently ischemia of choroid and retina,⁷ and eventually induce choroidal and retinal neovascularization. Pseudodrusen are derived from RPE cells and contain some components of drusen, but not all.³⁴ The presence of either pseudodrusen or drusen may indicate a disorder in the transport mechanism of the RPE that results in overproduction of secretions that may be inflammatory or toxic.⁴⁵ These secretions may damage adjacent RPE cells, leading to the death of dysfunctional RPE cells and the development of GA. Suzuki et al³⁰ speculated that dot and reticular (ribbon) pseudodrusen are different types rather than one being a more advanced version of the other; however, both types can become confluent. Thus,

confluent pseudodrusen seem to be the advanced version of dot pseudodrusen and reticular pseudodrusen. Confluent pseudodrusen, with larger lesion area and more drusenoid material than dot and reticular pseudodrusen, may be associated with more dysfunctional RPE cells and also may cause more damage to RPE cells, eventually leading to a higher risk of GA developing. Future longitudinal evaluation of how these 3 types of pseudodrusen progress over time will help to clarify the associations of each type of pseudodrusen with development of late AMD and will provide a better understanding of how pseudodrusen are related to the development of late AMD.

Although pseudodrusen are distinct from the conventional AMD phenotype (i.e., drusen), population-based studies have confirmed similar risk factors for both drusen and pseudodrusen, including increasing age, female gender, and smoking.⁴⁶ Similar to previous studies, we found pseudodrusen were more prevalent in women^{7,8,10,14,21,22} and in older subjects.^{10,11,14,47} However, smoking was not associated with pseudodrusen, likely because of the selective CATT participants with a high percentage of former smokers (51%) or current smokers (9%). The Beaver Dam Eye Study reported that patients with pseudodrusen had higher mortality rates,¹⁰ suggesting pseudodrusen may be a manifestation of a systemic disease such as cardiovascular disease. In our study, we did not find any difference between a history of cardiovascular disease and hypertension between subjects with and without pseudodrusen. Although we found a lower proportion with diabetes among subjects with pseudodrusen, conclusions must be made with caution. Retinal disease, such as choroidal neovascularization or subretinal fluid, can result in the fading or loss of pseudodrusen.^{3,8} We can speculate that diabetic retinopathy following the same mechanism may result in the low rate of pseudodrusen in diabetics.

Predicting progression from early to late AMD has high clinical usefulness. In 2005, the AREDS Study Group developed a simple AMD severity score for clinical use based on fundus photographic features (large drusen and pigment abnormalities) to predict the risk of progression to late AMD.¹⁷ In the AREDS scoring system, 1 point is added for having any large drusen and 1 point for any pigment abnormality (hyperpigmentation or depigmentation) in each eye. This simple AREDS scoring system is highly predictive of late AMD development.¹⁷ In our study, we found that pseudodrusen are an additional independent risk factor for late AMD development. Subjects with pseudodrusen had an approximately 2 times higher risk of late AMD developing than those without pseudodrusen across each level of the AREDS severity score. The baseline pseudodrusen improved the prediction for late AMD with the area under receiver operating characteristic curve improved from 0.64 (based on AREDS severity scale and dietary supplement use) to 0.68 ($P = 0.004$). This finding supports the inclusion of pseudodrusen evaluation along with large drusen and pigmentation abnormalities when predicting the development of late AMD. However, pseudodrusen evaluation requires additional grading time on CFP and other images (RF images, FA, etc.) by readers with expertise in pseudodrusen evaluation. The feasibility and validity of pseudodrusen evaluation in the clinical setting by busy

clinicians is uncertain. These factors need to be considered before applying the evaluation of pseudodrusen to clinical use. The cost effectiveness of applying pseudodrusen evaluation to clinical practice requires further investigation.

The strengths of this investigation include a large and well-characterized cohort of unilateral nAMD patients. The study has a few limitations. First, the CATT study participants are patients with active untreated nAMD. The results from this selective population may not be generalizable to the general AMD patients. Second, although the study has large sample size, the analyses by type of pseudodrusen (dot, reticular, and confluent) leads to smaller cases of pseudodrusen and lower statistical power for detecting their associations with late AMD. Our findings that the association of pseudodrusen with nAMD and GA varied with type of pseudodrusen need to be validated in future studies. Third, our evaluation of GA was based on CFP and FA findings. Not including SD OCT for GA determination may lead to the underestimate of GA, because early stages of GA may not be recognized by CFP and FA. Finally, we used fundus photographs to detect pseudodrusen that may lead to misclassification of pseudodrusen. The prevalence of pseudodrusen in our study (28.4%) was lower than in other studies of pseudodrusen in the fellow eye of patients with unilateral nAMD (34.6%–55.6%).^{21–25} Our proportion with pseudodrusen also was lower than the proportion (34.6%) from a study that used CFP and blue light photography.²¹ This difference could be the result of the older age of the CATT patients (mean age, 78 years vs. 74 years), because older patients have more media opacities that hamper the quality of CFP.^{8,37} If eyes with pseudodrusen are misclassified as being without pseudodrusen and these misclassified pseudodrusen have similar risk to our observed pseudodrusen, the RR for the association between pseudodrusen and late AMD may have been underestimated.⁴⁸ However, if the misclassified pseudodrusen are at earlier stage and signal lower risk of late AMD, the RR may have been overestimated.

In summary, baseline pseudodrusen in the fellow eye of CATT patients were associated with an approximately 2 times higher risk of late AMD developing through 2 years follow-up. The association with nAMD and GA varies with pseudodrusen type; dot pseudodrusen were associated most highly with nAMD, whereas confluent pseudodrusen were associated most highly with GA. The presence of pseudodrusen is an independent risk factor for progression to late AMD that confers considerable additional risk to eyes with large drusen or pigment abnormalities and should be considered when assessing the risk of late AMD.

References

- Mimoun G, Soubrane G, Coscas G. [Macular drusen]. *J Fr Ophthalmol* 1990;13:511–30.
- Zweifel SA, Spaide RF, Curcio CA, et al. Reticular pseudodrusen are subretinal drusenoid deposits. *Ophthalmology* 2010;117:303–312.e1.
- Sarks J, Arnold J, Ho IV, et al. Evolution of reticular pseudodrusen. *Br J Ophthalmol* 2011;95:979–85.
- Querques G, Srour M, Massamba N, et al. Reticular pseudodrusen. *Ophthalmology* 2013;120:872–878.e4.
- Spaide RF. Colocalization of pseudodrusen and subretinal drusenoid deposits using high-density en face spectral domain optical coherence tomography. *Retina* 2014;34:2336–45.
- Klein R, Davis MD, Magli YL, et al. The Wisconsin age-related maculopathy grading system. *Ophthalmology* 1991;98:1128–34.
- Arnold JJ, Sarks SH, Killingsworth MC, Sarks JP. Reticular pseudodrusen. A risk factor in age-related maculopathy. *Retina* 1995;15:183–91.
- Smith RT, Sohrab MA, Busuioc M, Barile G. Reticular macular disease. *Am J Ophthalmol* 2009;148:733–743.e2.
- Knudtson MD, Klein R, Klein BE, et al. Location of lesions associated with age-related maculopathy over a 10-year period: the Beaver Dam Eye Study. *Invest Ophthalmol Vis Sci* 2004;45:2135–42.
- Klein R, Meuer SM, Knudtson MD, et al. The epidemiology of retinal reticular drusen. *Am J Ophthalmol* 2008;145:317–26.
- Joachim N, Mitchell P, Rochtchina E, et al. Incidence and progression of reticular drusen in age-related macular degeneration: findings from an older Australian cohort. *Ophthalmology* 2014;121:917–25.
- Cohen SY, Dubois L, Tadayoni R, et al. Prevalence of reticular pseudodrusen in age-related macular degeneration with newly diagnosed choroidal neovascularisation. *Br J Ophthalmol* 2007;91:354–9.
- Zweifel SA, Imamura Y, Spaide TC, et al. Prevalence and significance of subretinal drusenoid deposits (reticular pseudodrusen) in age-related macular degeneration. *Ophthalmology* 2010;117:1775–81.
- Lee MY, Yoon J, Ham DI. Clinical characteristics of reticular pseudodrusen in Korean patients. *Am J Ophthalmol* 2012;153:530–5.
- Pieramici DJ, Bressler SB. Age-related macular degeneration and risk factors for the development of choroidal neovascularization in the fellow eye. *Curr Opin Ophthalmol* 1998;9:38–46.
- Prenner JL, Rosenblatt BJ, Tolentino MJ, et al. Risk factors for choroidal neovascularization and vision loss in the fellow eye study of CNVPT. *Retina* 2003;23:307–14.
- Ferris FL, Davis MD, Clemons TE, et al. A simplified severity scale for age-related macular degeneration: AREDS report no. 18. *Arch Ophthalmol* 2005;123:1570–4.
- Wong TY, Chakravarthy U, Klein R, et al. The natural history and prognosis of neovascular age-related macular degeneration: a systematic review of the literature and meta-analysis. *Ophthalmology* 2008;115:116–26.
- Rudnicka AR, Kapetanakis VV, Jarrar Z, et al. Incidence of late-stage age-related macular degeneration in American whites: systematic review and meta-analysis. *Am J Ophthalmol* 2015;160:85–93.e3.
- Maguire MG, Daniel E, Shah AR, et al. Incidence of choroidal neovascularization in the fellow eye in the comparison of age-related macular degeneration treatments trials. *Ophthalmology* 2013;120:2035–41.
- Pumariaga NM, Smith RT, Sohrab MA, et al. A prospective study of reticular macular disease. *Ophthalmology* 2011;118:1619–25.
- Finger RP, Wu Z, Luu CD, et al. Reticular pseudodrusen: a risk factor for geographic atrophy in fellow eyes of individuals with unilateral choroidal neovascularization. *Ophthalmology* 2014;121:1252–6.
- Hogg RE, Silva R, Staurenghi G, et al. Clinical characteristics of reticular pseudodrusen in the fellow eye of patients with unilateral neovascular age-related macular degeneration. *Ophthalmology* 2014;121:1748–55.

24. Sawa M, Ueno C, Gomi F, Nishida K. Incidence and characteristics of neovascularization in fellow eyes of Japanese patients with unilateral retinal angiomatous proliferation. *Retina* 2014;34:761–7.
25. Chang YS, Kim JH, Yoo SJ, et al. Fellow-eye neovascularization in unilateral retinal angiomatous proliferation in a Korean population. *Acta Ophthalmol* 2016;94:e49–53.
26. Comparison of Age-Related Macular Degeneration Treatments Trials Research Group, Martin DF, Maguire MG, et al. Ranibizumab and bevacizumab for neovascular age-related macular degeneration. *N Engl J Med* 2011;364:1897–908.
27. Comparison of Age-Related Macular Degeneration Treatments Trials Research Group, Martin DF, Maguire MG, et al. Ranibizumab and bevacizumab for treatment of neovascular age-related macular degeneration: two-year results. *Ophthalmology* 2012;119:1388–98.
28. Grunwald JE, Daniel E, Ying GS, et al. Photographic assessment of baseline fundus morphologic features in the Comparison of Age-Related Macular Degeneration Treatments Trials. *Ophthalmology* 2012;119:1634–41.
29. Grunwald JE, Daniel E, Huang J, et al. Risk of geographic atrophy in the Comparison of Age-Related Macular Degeneration Treatments Trials. *Ophthalmology* 2014;121:150–61.
30. Suzuki M, Sato T, Spaide RF. Pseudodrusen subtypes as delineated by multimodal imaging of the fundus. *Am J Ophthalmol* 2014;157:1005–12.
31. Lee MY, Yoon J, Ham DI. Clinical features of reticular pseudodrusen according to the fundus distribution. *Br J Ophthalmol* 2012;96:1222–6.
32. Spaide RF, Curcio CA. Drusen characterization with multimodal imaging. *Retina* 2010;30:1441–54.
33. Arnold JJ, Quaranta M, Soubrane G, et al. Indocyanine green angiography of drusen. *Am J Ophthalmol* 1997;124:344–56.
34. Rudolf M, Malek G, Messinger JD, et al. Sub-retinal drusenoid deposits in human retina: organization and composition. *Exp Eye Res* 2008;87:402–8.
35. Alten F, Heiduschka P, Clemens CR, Eter N. Multifocal electroretinography in eyes with reticular pseudodrusen. *Invest Ophthalmol Vis Sci* 2012;53:6263–70.
36. Querques G, Querques L, Martinelli D, et al. Pathologic insights from integrated imaging of reticular pseudodrusen in age-related macular degeneration. *Retina* 2011;31:518–26.
37. Ueda-Arakawa N, Ooto S, Tsujikawa A, et al. Sensitivity and specificity of detecting reticular pseudodrusen in multimodal imaging in Japanese patients. *Retina* 2013;33:490–7.
38. Schmitz-Valckenberg S, Alten F, Steinberg JS, et al. Reticular drusen associated with geographic atrophy in age-related macular degeneration. *Invest Ophthalmol Vis Sci* 2011;52:5009–15.
39. Querques G, Querques L, Forte R, et al. Choroidal changes associated with reticular pseudodrusen. *Invest Ophthalmol Vis Sci* 2012;53:1258–63.
40. Garg A, Oll M, Yzer S, et al. Reticular pseudodrusen in early age-related macular degeneration are associated with choroidal thinning. *Invest Ophthalmol Vis Sci* 2013;54:7075–81.
41. Grewal DS, Chou J, Rollins SD, Fawzi AA. A pilot quantitative study of topographic correlation between reticular pseudodrusen and the choroidal vasculature using en face optical coherence tomography. *PLoS One* 2014;9:e92841.
42. Haas P, Esmaelpour M, Ansari-Shahrezaei S, et al. Choroidal thickness in patients with reticular pseudodrusen using 3D 1060-nm OCT maps. *Invest Ophthalmol Vis Sci* 2014;55:2674–81.
43. Yoneyama S, Sakurada Y, Mabuchi F, et al. Genetic and clinical factors associated with reticular pseudodrusen in exudative age-related macular degeneration. *Graefes Arch Clin Exp Ophthalmol* 2014;52:1435–41.
44. Flamendorf J, Agron E, Wong WT, et al. Impairments in dark adaptation are associated with age-related macular degeneration severity and reticular pseudodrusen. *Ophthalmology* 2015;122:2053–62.
45. Spaide RF. Outer retinal atrophy after regression of subretinal drusenoid deposits as a newly recognized form of late age-related macular degeneration. *Retina* 2013;33:1800–8.
46. Saade C, Smith RT. Reticular macular lesions: a review of the phenotypic hallmarks and their clinical significance. *Clin Experiment Ophthalmol* 2014;42:865–74.
47. Puche N, Blanco-Garavito R, Richard F, et al. Genetic and environmental factors associated with reticular pseudodrusen in age-related macular degeneration. *Retina* 2013;33:998–1004.
48. Szatmari P, Jones MB. Effects of misclassification on estimates of relative risk in family history studies. *Genet Epidemiol* 1999;16:368–81.

Footnotes and Financial Disclosures

Originally received: October 28, 2015.

Final revision: January 29, 2016.

Accepted: February 23, 2016.

Available online: April 1, 2016.

Manuscript no. 2016-20.

¹ Department of Ophthalmology, Beijing Chaoyang Hospital, Capital Medical University, Beijing, People's Republic of China.

² Department of Ophthalmology, Scheie Eye Institute, Perelman School of Medicine, University of Pennsylvania, Philadelphia, Pennsylvania.

³ Cole Eye Institute, Cleveland Clinic, Cleveland, Ohio.

*A listing of the Comparison of Age-Related Macular Degeneration Treatments Trials Research Group is available at www.aaojournal.org.

Financial Disclosure(s):

The author(s) have no proprietary or commercial interest in any materials discussed in this article.

Supported by the National Eye Institute, National Institutes of Health, Bethesda, Maryland (cooperative agreement nos.: U10 EY017823, U10 EY017825, U10 EY017826, U10 EY017828, and R21EY023689).

Author Contributions:

Conception and design: Zhou, Daniel, Maguire, Grunwald, Martin, Ying

Analysis and interpretation: Zhou, Daniel, Maguire, Grunwald, Martin, Ying

Data collection: Zhou, Daniel, Maguire, Grunwald, Martin, Martin, Ying

Obtained funding: none

Overall responsibility: Zhou, Daniel, Maguire, Grunwald, Martin, Martin, Ying

Abbreviations and Acronyms:

AMD = age-related macular degeneration; **AREDS** = Age-Related Eye Diseases Study; **aRR** = adjusted risk ratio; **CATT** = Comparison of Age-Related Macular Degeneration Treatments Trials; **CFP** = color fundus photography; **CI** = confidence interval; **FA** = fluorescein angiography; **GA** = geographic atrophy; **nAMD** = neovascular age-related macular degeneration; **OCT** = optical coherence tomography; **PRN** = pro re nata; **RF** = red-free; **RPE** = retinal pigment epithelium; **RR** = risk ratio; **SD** = spectral-domain.

Correspondence:

Gui-shuang Ying, PhD, Department of Ophthalmology, Scheie Eye Institute, Perelman School of Medicine, University of Pennsylvania, 3535 Market Street, Suite 700, Philadelphia, PA 19104. E-mail: gsying@mail.med.upenn.edu.